Original Article

# Comparison of Clinical Effectiveness between the Management of Cervical and Lumbar Disc Herniation with Percutaneous Laser Disc Decompression Followed by Interlaminar Cervical Epidural and Lumbar Transforaminal Epidural Steroid Injection Respectively

**Shantanu Mallick**

Department of Pain and Palliative Care, MGM Medical College and Hospital, Navi Mumbai, Maharashtra, India

## Abstract

**Background:** Different treatments for discogenic axial back/neck pain or radicular pain to limbs are there from conservative therapies and minimally invasive therapies to open spine surgeries with lots of controversial outcomes. Percutaneous laser disc decompression (PLDD) is one of the minimally invasive therapies which is done under local anesthesia and has been successfully performed in many selected patients for their lumbar and cervical disc herniation problems. In PLDD, a part of the nucleus pulposus is vaporized with the help of laser energy to reduce the intradiscal pressure of the diseased discs causing nerve compression. In this case series after a 1-year follow-up, the clinical effectiveness of PLDD with epidural steroid injection is assessed in selected lumbar and cervical disc herniation cases. **Materials and Methods:** Ninety-six patients underwent the PLDD procedure at the cervical and lumbar disc with epidural steroid injections for their disc herniation causing radicular pain in the upper and lower limbs, respectively. The patients were followed at 8 weeks, 3 months, 6 months, and 1 year. The main outcome measures were done through the visual analog scores (VASs) and the Oswestry Disability Index (ODI) for upper and lower limb pain. **Results:** The primary outcome showed that there is a significant clinically relevant difference between the two groups at a 1-year follow-up. VAS and mean disability score based on the ODI were significantly lower in cervical disc herniation patients. The reoperation rate in the cervical group is also much less than the lumbar group. **Conclusion:** Like all other surgical modalities for disc herniation, PLDD has its own advantages and disadvantages. However, compared to lumbar disc herniation, it may give better results in cervical disc herniation. In selected cases, combined PLDD with epidural steroid injection can be chosen as a "first-choice-minimally-invasive-treatment," when standard conservative therapies do not give satisfactory outcome.

**Keywords:** Cervical disc herniation, cervical epidural steroid injection and lumbar transforaminal epidural steroid injections, diode laser, lumbar disc herniation, percutaneous laser disc decompression

**Received: 20-12-2022** **Revised: 23-08-2023** **Accepted: 24-08-2023** **Published: 13-12-2023**

## Introduction

Back pain, whether axial or radiating in nature in cervical and lumbar zones, is one of the major chronic debilitating conditions in our day-to-day life throughout the world which involves a huge loss of money, absence of work, waste of quality time, and psychological impact.[1]

In most patients, conservative therapies with lifestyle changes help to bring them into normal condition within 6 weeks of time, but in refractory cases, a thorough diagnosis of pain generators followed by specific interventions with the lifestyle changes helps to give a long-term pain relief. For radiating pain to limbs,

Access this article online

Quick Response Code:

Website: https://journals.lww.com/ijpn

DOI: 10.4103/ijpn.ijpn_124_22

**Address for correspondence:** Dr. Shantanu Mallick, MGM Medical College and Hospital, Navi Mumbai, Maharashtra, India. E-mail: drmallick@rediffmail.com

This is an open access journal, and articles are distributed under the terms of the Creative Commons Attribution-NonCommercial-ShareAlike 4.0 License, which allows others to remix, tweak, and build upon the work non-commercially, as long as appropriate credit is given and the new creations are licensed under the identical terms.

**For reprints contact:** WKHLRPMedknow_reprints@wolterskluwer.com

**How to cite this article:** Mallick S. Comparison of clinical effectiveness between the management of cervical and lumbar disc herniation with percutaneous laser disc decompression followed by interlaminar cervical epidural and lumbar transforaminal epidural steroid injection respectively. Indian J Pain 2023;37:178-83.

usually the most common cause is disc herniation causing nerve root compression, for which "open-surgical-discectomy" is the well-accepted treatment despite having risks and complications.[2] Lots of advancement have been going on through the modern minimally invasive spine techniques to avoid tissue trauma as well as a high rate of complications and re-surgery to increase the patients' satisfaction.

Percutaneous Laser Disc Decompression (PLDD) is another way to decompress the nerve by decreasing the intradiscal pressure, evaporating the nucleus pulposus, and delivering laser energy into it which subsequently causes a decrease in intradiscal pressure and releases the nerve root by the reduction of herniation.[3] PLDD was first performed by Choy *et al*. in 1986, and the US Food and Drug Administration (FDA) approved PLDD for use in the USA in 1991.[4] Several cohort studies were published, and even FDA approval also was given, but no randomized trial has been performed till now. No concrete evidence about the efficacy and the cost-effectiveness of PLDD with respect to conventional surgeries is not available.[5]

### Aims and objectives

In many cases of cervical and lumbar disc herniation causing radiating pain in the upper limb, cervical epidural steroid injection (CESI) and transforaminal epidural steroid injection (TFESI) are commonly given to reduce the neuropathic pain. That is why to avoid the "open-surgical-discectomy" in selected cases PLDD followed by CESI or can be tried to see the outcome as PLDD may reduce the intradiscal pressure which may reduce the disc herniation followed by CESI or TFESI to reduce the inflammation of neuropathic pain.

## Materials and Methods

Ninety-six patients (between 18- and 60-year age) were chosen who were suffering from radiating pain in the upper and lower limbs due to cervical and lumbar disc herniation in single or multiple levels. They were not ready for open surgery after knowing about the PLDD which may help them to avoid the open surgery.

They were kept in two groups: Forty patients were kept in Group A for the cervical disc PLDD and 56 patients were kept in Group B for the lumbar disc PLDD.

| Group A: Forty cases | |
|---|---|
| **Disc distribution** | **Number of cases** |
| C3-4 | 4 |
| C4-5 | 4 |
| C5-6 + C6-7 | 20 |
| C6-7 | 12 |

| Group B: 56 cases | |
|---|---|
| **Disc distribution** | **Number of cases** |
| L2-3 | 1 |
| L3-4 | 3 |
| L3-4 + L4-5 + L5-S1 | 4 |
| L4-5 | 20 |
| L4-5 + L5-S1 | 18 |
| L5-S1 | 10 |

All the patients have gone through the conservative therapies for a minimum of 6 weeks but have not responded well. All of them were advised for conventional spine surgeries with or without screw fixations. However, they were not willing for surgery and agreed for PLDD therapy if they can avoid the surgery. The exclusion criteria were local or systemic infections, segmental instability or spondylolisthesis, neoplastic diseases, apparent mental disorder, pregnancy, too old patients with calcified disc, cauda equina syndrome, severe canal stenosis, facet hypertrophy, reduced disc height of more than 50%, previous spine surgery, annular tear, sequestrated disc, and disc bulge encroaching more than 1/2 of the spinal canal.

All the patients selected for this case series were having contained herniation which was <1/2 of the spinal canal and radiating pain to the unilateral or bilateral limbs due to nerve compression. Informed consent, preoperative 4 h fasting, IV-line, prophylactic antibiotics (injection cefuroxime 1.5G), preoperative IV antacids and antiemetics, and monitoring were followed for all the cases. All the PLDD procedures were done according to Choy *et al*. technique[4] by the author between December 2017 and December 2019. All the cases were done under local anesthesia without any sedation under fluoroscopic C-arm guidance.

After performing PLDD in the supine position through the anterior approach in Group A patients, interlaminar CESI was given under fluoroscopy guidance in prone position by 18G Tuohy needle at C6–7 or C7–T1 level with 6 mL solution of 0.125% bupivacaine and 60 mg triamcinolone.

After performing PLDD in Group B patients after performing PLDD in the prone position, TFESI was given under fluoroscopy guidance on the same position at selected levels by 23G spinal needle with maximum 2 mL at each level taking a total dose of 0.125% bupivacaine with 60–80 mg triamcinolone.

Time duration for single-level cervical or lumbar procedure was approximately 60 min including epidural injections. Multiple levels took extra time accordingly.

| Distribution of patients with their parameters | | | | | | | |
|---|---|---|---|---|---|---|---|
| | **Male above 40/below 40** | **Female above 40/below 40** | **Affected levels** | **Obese patients (BMI=28–31)** | **Coagulopathy** | **HTN** | **DM** |
| Group A | 16/14 | 7/5 | C3-4–C6-7 | 12 | No | 3 | 2 |
| Group B | 17/19 | 11/9 | L2-3–L5-S1 | 15 | No | 5 | 3 |

HTN: Hypertension, BMI: Body mass index, DM: Diabetes mellitus

All the cases were performed in Vinamra Swaraj Hospital, Navi Mumbai.

## Techniques

### *Cervical percutaneous laser disc decompression*

The procedure was done under local anesthesia by a 10 cm/18G long spinal needle. Before starting the needling procedure, first the needle is attached with Y connector and then the laser fiber is introduced through the "Y-connector-attached-needle" keeping the laser fiber 2–3 mm out of the needle tip and laser fiber is locked at this length by the proximal end of Y connector so that when the needle is put inside the disc, the exact length (2–3 mm) of the fiber comes out of the needle tip inside the nucleus [Figure 1]. Then, after adequate aseptic precaution needling was performed in the supine position under local anesthesia under fluoroscopy guidance through the anterior approach, pushing the trachea and esophagus together (enclosed in the pretracheal fascia) on one side and carotid sheath on the other side by fingers and placing the needle tip at the center of the disc and at the middle of the endplates to avoid the burning of endplates as well as to deposit maximum laser heat at the nucleus[6] [Figures 2 and 3]. Then, the 0.4 mm laser fiber (locked with Y connector) was put into the nucleus pulposus through the 10 cm/18G needle. Now, laser energy was delivered in the cervical discs following the protocols mentioned below. After finishing PLDD procedure, both the fiber and the needle are removed, and the puncture site is covered with a sterile dressing. Then, the patient was positioned in prone for CESI under fluoroscopy guidance.

### *Lumbar percutaneous laser disc decompression*

Same procedure is followed for the preparation of laser fiber with Y connector, but with the 15 cm/18G needle, keeping the laser fiber 3–4 mm out of the needle tip. Then, after adequate aseptic precaution needling was performed under fluoroscopy guidance in such a way that the needle tip should be at the center of the disc and the middle of the endplates so that laser heat energy does not affect the endplates and will only be restricted to the nucleus [Figures 4 and 5]. Then, the 0.4 mm laser fiber (locked with Y connector) was put into the nucleus pulposus through the 15 cm/18G needle.[7] Now, laser energy was delivered in the lumbar discs following the protocols mentioned below. After finishing PLDD procedure, both the fiber and the needle are removed, and the puncture site is covered with a sterile dressing. Then, the patients were positioned for lumbar TFESI at the respective levels as per the magnetic resonance imaging reports.

For all the cases, 980 nm wavelength/9W diode laser machine (Berylas Diode Laser) was used with 1 sec pulse length and 3 sec interval length [Figure 6]. For cervical disc, 300–400 Joules energy was used, and for lumbar discs, 1000–1500 Joules energy was used. Maximum energy (1500 J) was used at L4–5 level.[8] Most of the patients were under insurance coverage, for which they were kept admitted for 24 h, but 25% of patients were discharged after 1 h of observation for whom the procedures were done on the outpatient department basis. All the patients were advised to take bed rest for a week, followed by resumption of daily activities, postoperative antibiotics (tablet cefuroxime 500 mg) for 3 days, analgesics, muscle relaxants for 1 week, and neuropathic pain medications (pregabalin 50 mg BD/HS) for 1 month or more and physiotherapy as per requirements.

## Results

The results of PLDD might take a slightly longer period for full recovery compared to "gold standard" open surgery or microsurgery, for which cervical interlaminar epidural steroid injection and TFESIs were given at the specific nerve roots in Groups A and B, respectively, to reduce the inflammation of the nerve roots during the recovery period. That is why in this case series, the primary follow-up for the assessment of pain and disability was kept at 8 weeks, and further follow-ups were kept at 3 months, 6 months, and 1 year.

As per the visual analog scoring and the Oswestry Disability Index (ODI) assessment, the results are as follows:

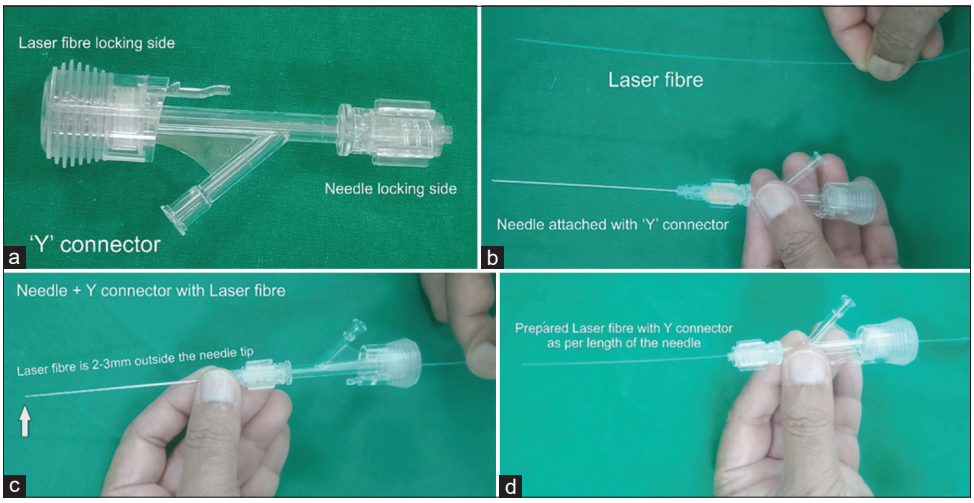


**Figure 1:** (a-d) Preparation of laser fiber

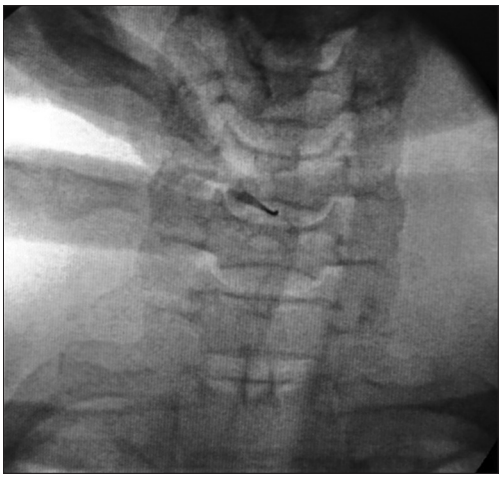

**Figure 2:** Needle placement in the anterior posterior view

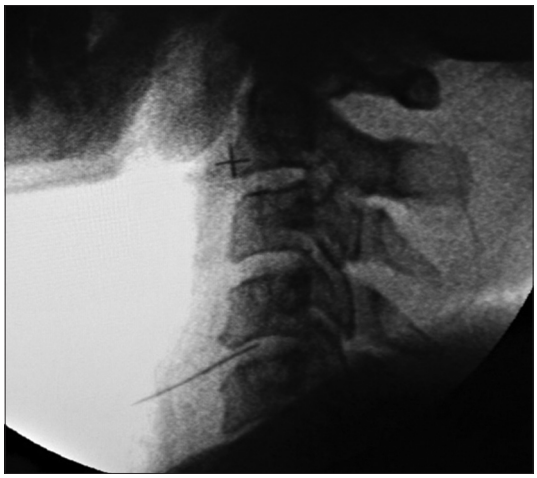

**Figure 3:** Needle placement in the lateral view

**Figure 4:** Needle placement in the anterior posterior view

**Figure 5:** Needle placement in the lateral view

Group A: 82.5% ($n$ = 33) showed an excellent or good outcome (visual analog scores [VASs] came down from 2.5 ± 0.4 to 6.8 ± 0.7, $P < 0.001$), and and mean ODI came down significantly (from 37.2 ± 0.6 to 21.1 ± 0.4, $P < 0.001$) in 1-year follow-up. However, 17.5% ($n$ = 7) showed mild changes or no changes (VAS came down from 5.3 ± 0.5 to 6.9 ± 0.6) and mean ODI did not came down significantly (from 36.5 ± 0.7 to 31.3 ± 0.3, $P < 0.001$) in 1-year follow-up and that is why they ultimately underwent open surgery.

Group B: 55.3% ($n$ = 31) showed an excellent or good outcome (VAS came down from 2.6 ± 0.3 to 6.9 ± 0.3, $P < 0.001$) and and mean ODI came down significantly (from 38.2 ± 0.4 to 22.1 ± 0.6, $P < 0.001$) in 1-year follow-up, whereas 44.6% ($n$ = 23) showed mild changes or no changes (VAS came down from 5.8 ± 0.3 to 6.9 ± 0.3) and mean ODI did not came down significantly (from 37.6 ± 0.8 to 32.3 ± 0.4, $P < 0.001$) in 1-year follow-up and they had to undergo open surgery.

Comparatively, the improvement came more quickly and sustained in the cervical group than in the lumbar group. Patients who are below 40 years old got better relief. No complications are occurred in both groups.

## Discussion

Diode laser or semiconductor laser was first developed in the early 1960s by Robert N. Hall of general electric and because of its compactness and cost-effectiveness, it is now maximally used in the whole world what we regularly watch in DVD players, laser printers, barcode scanners, fiber-optic phone lines, laser pointers, etc., but it is a low-powered diode laser.[9] For medical therapeutic purposes, diode laser is developed with the different powerful outputs with the different wavelengths such as 10W, 15W, 30W, and 980 nm, 1064 nm, or 1470 nm, which meet the needs for a variety of applications such as spider vein removal (varicose veins), nail fungus treatment, dentistry, PLDD, laser pain relief, and veterinary. Different other types of lasers (Nd: YAG laser, Ho: YAG laser, KTP laser, and Co2 laser) have also been used for PLDD therapies with lots of controversial outcomes.[10]

Intervertebral disc can be compared with a closed hydraulic system, consisting of a nucleus pulposus which contains a huge amount of water surrounded by a fibrocartilaginous ring and annulus fibrosus. The increasing water content of the

**Figure 6:** Berylas diode laser

nucleus pulposus causes an excessive increase in intradiscal pressure. It is seen in *in vitro* experiments that a 1 mL of volume increase can causes a rise of intradiscal pressure up to 312 kPa (2340 mmHg).[4] If intradiscal pressure is reduced, herniated material may come toward the center of the disc which causes a reduction of nerve root compression and relief of symptoms. This mechanism is applied in the contained herniated disc cases by the PLDD technique, evaporating the water inside the nucleus pulposus by the laser energy. This increased heat also causes protein denaturation and subsequent renaturation, leading to structural changes in the nucleus pulposus which limits the capability of water attraction and ultimately causes a reduction in intradiscal pressure by almost 50%–57%.[11,12]

Technically, cervical disc needle placement through anterior approach is more challenging than lumbar disc needle placement in our day-to-day pain management practice. Safety zones at different levels are different. One must be very careful about the carotid artery in between sternocleidomastoid muscle laterally and trachea with esophagus medially. As pretracheal fascia enclosing larynx, trachea, pharynx, esophagus, thyroid, and parathyroid glands together, when we push trachea medially, it is increasing the safety zone at the midline during the initial disc puncture. Carotid artery is more medial at the C3–4 level and more lateral at C6–7 level. That is why a more lateral puncture from midline increases the risk of carotid puncture and more medial puncture increases the risk of airway and esophagus injury. Safest needle entry should be between airway and pulsating carotid artery. At C3–4, one has to be careful about the injury of superior thyroidal artery in between hyoid bone and thyroid cartilage. At C5–6/C6–7, safety margin is larger, but at C7–T1, little more medial approach is recommended to avoid lung apex injury.[6]

Risks may be there with high energy causing unwanted tissue burns, but low-energy lasers may cause insufficient decompression. One of the serious complications of any disc procedure is spondylodiscitis. In PLDD therapy, discitis can be aseptic as well as septic. Due to high-energy damage may occur at disc or endplates causing aseptic discitis. That is why careful monitoring of patient's complaints is needed during procedure adjusting the laser power, pulse rate, and pulse interval if patient complains of pain during PLDD. Our main is to decompress the nucleus pulposus but not to damage the annulus fibrosus.[11,13-15] When a patient complains of pain during PLDD, it is better to keep a longer pulse interval or lower power setting so that heat generated by the laser energy gets time to dissipate which prevents the structural damage to the surrounding tissues.[16] To avoid septic discitis, utmost sterility during procedure is mandatory and double-needle technique should be followed. The use of additional antibiotic prophylaxis also supports to reduce the risk of septic discitis.[13,15]

## Conclusion

Although PLDD is being used for more than 20 years, scientific proof of its efficacy is still controversial. In this case series, the follow-up of 1 year is not a very long period, that is why the author will definitely update the further outcome in the coming years. The author is concluding that PLDD can be an economical and safe "first-choice-minimally-invasive-technique" for the selected disc herniation cases which are not responding to the standard conservative therapies.

### Financial support and sponsorship

Nil.

### Conflicts of interest

There are no conflicts of interest.

## References

1. van den Akker-van Marle ME, Brouwer PA, Brand R, Koes B, van den Hout WB, van Buchem MA, *et al.* Percutaneous laser disc decompression versus microdiscectomy for sciatica: Cost utility analysis alongside a randomized controlled trial. Interv Neuroradiol 2017;23:538-45.
2. Radcliff K, Vaccaro AR, Hilibrand A, Schroeder GD. Lasers in spine surgery. J Am Acad Orthop Surg 2019;27:621-32.
3. Momenzadeh S, Koosha A, Kazempoor Monfared M, Bairami J, Zali A, Ommi D, *et al.* The effect of percutaneous laser disc decompression on reducing pain and disability in patients with lumbar disc herniation. J Lasers Med Sci 2019;10:29-32.
4. Choy DS, Michelsen J, Getrajdman G, Diwan S. Percutaneous laser disc decompression: An update – Spring 1992. J Clin Laser Med Surg 1992;10:177-84.
5. Choy DS. Percutaneous Laser Disc Decompression: A Practical Guide. New York: Springer-Verlag; 2003. p. 223-8.
6. Lee SH, Lee JH, Choi WC, Jung B, Mehta R. Anterior minimally invasive approaches for the cervical spine. Orthop Clin North Am 2007;38:327-37.
7. Choy DS, Case RB, Fielding W, Hughes J, Liebler W, Ascher P. Percutaneous laser nucleolysis of lumbar disks. N Engl J Med 1987;317:771-2.
8. Gevargez A, Groenemeyer DW, Czerwinski F. CT-guided percutaneous laser disc decompression with Ceralas D, a diode laser with 980-nm wavelength and 200-microm fiber optics. Eur Radiol 2000;10:1239-41.
9. Woodford C. Semiconductor Diode laser. Available from: https://www.explainthatstuff.com/semiconductorlaserdiodes.html. [Last updated on 2023 Jul 26].
10. Schenk B, Brouwer PA, Peul WC, van Buchem MA. Percutaneous laser disk decompression: A review of the literature. AJNR Am J Neuroradiol 2006;27:232-5.

11. Gangi A, Dietemann JL, Gasser B, Guth S, de Unamuno S, Fogarrassi E, *et al.* Interventional radiology with laser in bone and joint. Radiol Clin North Am 1998;36:547-57.
12. Steiner P, Zweifel K, Botnar R, Schoenenberger AW, Debatin JF, von Schulthess GK, *et al.* MR guidance of laser disc decompression: Preliminary *in vivo* experience. Eur Radiol 1998;8:592-7.
13. Bosacco SJ, Bosacco DN, Berman AT, Cordover A, Levenberg RJ, Stellabotte J. Functional results of percutaneous laser discectomy. Am J Orthop (Belle Mead NJ) 1996;25:825-8.
14. Siebert WE, Berendsen BT, Tollgaard J. Percutaneous laser disk decompression. Experience since 1989. Orthopade 1996;25:42-8.
15. Choy DS. Percutaneous laser disc decompression (PLDD): Twelve years' experience with 752 procedures in 518 patients. J Clin Laser Med Surg 1998;16:325-31.
16. Turgut M, Onol B, Kiliniç K, Tahta K. Extensive damage to the end-plates as a complication of laser discectomy. An experimental study using an animal model. Acta Neurochir (Wien) 1997;139:404-9.